

Update in Adrenocortical Carcinoma

Martin Fassnacht, Matthias Kroiss, and Bruno Allolio

Medizinische Klinik und Poliklinik IV (M.F.), Klinikum der Universität München, 80336 Munich, Germany; Comprehensive Cancer Center Mainfranken (M.F., M.K.), University of Würzburg, 97080 Würzburg, Germany; and Department of Internal Medicine I-Endocrine and Diabetes Unit (B.A.), University Hospital, University of Würzburg, 97080 Würzburg, Germany

Adrenocortical carcinoma (ACC) is an orphan malignancy that has attracted increasing attention during the last decade. Here we provide an update on advances in the field since our last review published in this journal in 2006.

The Wnt/ β -catenin pathway and IGF-2 signaling have been confirmed as frequently altered signaling pathways in ACC, but recent data suggest that they are probably not sufficient for malignant transformation. Thus, major players in the pathogenesis are still unknown.

For diagnostic workup, comprehensive hormonal assessment and detailed imaging are required because in most ACCs, evidence for autonomous steroid secretion can be found and computed tomography or magnetic resonance imaging (if necessary, combined with functional imaging) can differentiate benign from malignant adrenocortical tumors. Surgery is potentially curative in localized tumors. Thus, we recommend a complete resection including lymphadenectomy by an expert surgeon. The pathology report should demonstrate the adrenocortical origin of the lesion (eg, by steroidogenic factor 1 staining) and provide Weiss score, resection status, and quantitation of the proliferation marker Ki67 to guide further treatment. Even after complete surgery, recurrence is frequent and adjuvant mitotane treatment improves outcome, but uncertainty exists as to whether all patients benefit from this therapy.

In advanced ACC, mitotane is still the standard of care. Based on the FIRM-ACT trial, mitotane plus etoposide, doxorubicin, and cisplatin is now the established first-line cytotoxic therapy. However, most patients will experience progress and require salvage therapies. Thus, new treatment concepts are urgently needed. The ongoing international efforts including comprehensive “-omic approaches” and next-generation sequencing will improve our understanding of the pathogenesis and hopefully lead to better therapies. (*J Clin Endocrinol Metab* 98: 4551–4564, 2013)

The interest in adrenocortical carcinoma (ACC) has increased tremendously in the last decade. In only 12 years, more literature has been published than in the 50 years before. Here we provide an update of the major advances in the field since our review published in the *JCEM* in 2006 (1). We performed a PubMed search of all articles published between January 2006 and June 2013

using the terms “adrenocortical carcinoma,” “adrenal cancer,” and “mitotane” (n = 985), and we screened the database at www.clinicaltrials.gov and abstracts of the annual meetings of The Endocrine Society and the American Society of Clinical Oncology (ASCO). We identified some 220 publications as most relevant, but due to space limitations, not all papers could be included. The recom-

ISSN Print 0021-972X ISSN Online 1945-7197

Printed in U.S.A.

Copyright © 2013 by The Endocrine Society

Received July 31, 2013. Accepted September 24, 2013.

First Published Online September 30, 2013

Abbreviations: ACC, adrenocortical carcinoma; CT, computed tomography; EDP, etoposide, doxorubicin, cisplatin; EDP-M, EDP and mitotane; ENSAT, European Network for the Study of Adrenal Tumors; FIRM-ACT, First International Randomized trial in locally advanced and Metastatic Adrenocortical Carcinoma Treatment; HR, hazard ratio; HU, Hounsfield units; LND, lymph node dissection; miR, microRNA; MRI, magnetic resonance imaging; mTOR, mammalian target of rapamycin; SF1, steroidogenic factor 1; Sz-M, streptozotocin and mitotane; TKI, tyrosine kinase inhibitor; VEGF, vascular endothelial growth factor.

recommendations of this review represent our personal view because the level of evidence in many areas of ACC remains low. However, we specifically acknowledge areas of particular uncertainty.

Epidemiology

ACC is a rare and highly aggressive malignancy with an annual incidence of 0.7–2.0 cases per million population (2, 3). ACC can occur at any age, with a peak incidence between 40 and 50 years, and women are more often affected (55–60%). The incidence in children is particularly high in southern Brazil due to the high prevalence (0.27%) of a specific TP53 germline mutation (R337H) (4).

Molecular Pathogenesis

The understanding of the molecular events underlying the pathogenesis of ACC has improved in recent years but is not yet satisfactory. Table 1 provides a selection of the most important molecular changes in ACC.

The two most frequent alterations observed in ACC so far are overexpression of IGF-2 (5–7) and constitutive activation of the Wnt/ β -catenin pathway (8, 9). IGF-2 overexpression in sporadic ACC results mainly from duplication of the paternal allele (paternal unidisomy) and is associated with altered epigenetic imprinting at 11p15 (10). In vitro inhibition of IGF-2 signaling by blocking

IGF-1 receptor agents reduced ACC cell proliferation (11). Activation of the Wnt/ β -catenin pathway occurs in both adrenal adenomas and ACC (12–14) and is frequently caused by activating mutations of the gene encoding β -catenin (15). In patients with ACC, β -catenin activation—as confirmed by the presence of β -catenin nuclear staining—is associated with decreased overall survival (15, 16) indicating that this staining carries important clinical information. IGF-2 overexpression in transgenic animal models did not result in adrenal tumor development, although the IGF signaling pathway was activated (16, 17). Activation of the Wnt/ β -catenin pathway in the adrenal cortex led to adrenal tumors, but only a few had malignant characteristics (8). Similarly, the combination of IGF-2 overexpression and Wnt activation induced only a slightly more malignant phenotype (16).

Steroidogenic factor 1 (SF1) plays an important role in adrenal development and is frequently overexpressed in adrenocortical tumors (18, 19). Furthermore, SF1 increases proliferation in human adrenocortical tumor cells (20), and high expression of SF1 in ACC is associated with poor survival (18, 21). Thus, SF1 may become an important therapeutic target because SF1 inverse agonists have been shown to inhibit adrenocortical cell proliferation in vitro (22).

Germline mutations in the TP53 tumor suppressor gene have been observed in 50–80% of children with ACC, indicating the presence of a Li-Fraumeni syndrome with susceptibility to a variety of further malignancies. A small

Table 1. Genetic Alterations in ACC and Their Clinical Implications

Affected Genes	Alteration in ACC	Clinical Impact
TP53	Germline mutation in children (60–80%) and adults (around 4%) (23, 24) Somatic mutations (25–35%) and loss of heterozygosity in adult sporadic ACC	Li-Fraumeni syndrome with increased prevalence of other malignancies Poor prognosis
CTNNB1	Activating mutations or other activation of the Wnt/ β -catenin pathway (8, 9, 15)	Occurs also in adenomas, aggressive phenotype in ACC (9, 16)
11p15 locus (IGF-2, H19, CDKN1c)	Germline mutations in Beckwith-Wiedemann syndrome, paternal unidisomy in sporadic ACC leading to high expression of IGF-2 (10)	No clear relationship to prognosis due to almost uniform overexpression of IGF-2 (90% of cases)
SF1	Overexpression in both childhood and adult sporadic ACC (18, 19)	High expression is associated with impaired prognosis (18, 21)
CpG islands	Hypermethylation with low expression of tumor suppressor genes (33, 34)	Extensive hypermethylation negatively affects prognosis
Mismatch repair genes	Germline mutations in 3.2% of ACC cases (25)	Lynch syndrome
BUB1 and PINK1	High expression of BUB1 together with low expression of PINK1 (26)	Separation of poor prognosis ACC from less aggressive tumors
Micro RNAs	Altered expression profiles (eg, high miR 483 5 p) possibly related to TARBP2 overexpression (29–31)	Predictors of prognosis, miR 483 5 p in serum may serve as biomarker for aggressive ACC (32)
Jag1	Up-regulation of both mRNA expression and protein levels (28)	Correlates with tumor grade and tumor stage

but significant percentage (~4%) of adult ACC patients (23, 24) carries a germline mutation in the TP53 gene, raising the question whether adults should be screened for TP53 mutations because this may impact on the future care of the affected patients and their relatives. Furthermore, somatic mutations of TP53 in tumor tissue or loss of heterozygosity at the TP53 locus is found in more than 50% of adult patients with ACC, and TP53 mutated tumors are associated with an aggressive phenotype (13). In a recent study, 3.2% of ACCs were associated with germline mutations of mismatch repair genes as part of the Lynch syndrome (25).

Gene expression profiling has further contributed to the understanding of the molecular pathogenesis of ACC. Unsupervised cluster analyses of transcriptome data permitted the identification of subgroups with different prognosis (26, 27). Furthermore, the expression of the two genes DLG7 and PINK1 allowed the discrimination of benign from malignant adrenocortical tumors, and the combined analysis of BUB1 and PINK1 identified subgroups of ACC with greatly differing prognoses.

Further pathways potentially involved in the pathogenesis of ACC include changes in Notch signaling (28) and alterations in adrenocortical microRNA profiles (29–31). Of note, high serum miR 483 5p was found to be a useful biomarker for poor prognosis ACC (32). In addition, hypermethylation of CpG islands has been observed in ACC compared to adrenal adenomas and was shown to lead to suppression of tumor suppressor genes and negatively affect the prognosis of ACC (33, 34).

Diagnostic Workup

In recent years several reviews have covered the diagnostic workup of adrenal lesions (35–39). We therefore only summarize principles and highlight some recent advances.

Endocrine workup

In 2005, the European Network for the Study of Adrenal Tumors (ENSAT) suggested a preoperative laboratory workup for suspected ACC (www.ensat.org/). It comprises assessment of basal cortisol, ACTH, dehydroepiandrosterone sulfate, 17-hydroxyprogesterone, androstenedione, testosterone, and estradiol as well as a dexamethasone suppression test and urinary free cortisol excretion. The aldosterone/renin ratio is measured in patients with hypertension or hypokalemia. Although the cost effectiveness of this approach is unproven, we still consider this extensive panel to be useful for several reasons: it may prove the adrenocortical origin of the lesion, suggest malignancy, and document autonomous gluco-

corticoid excess that, if missed, regularly entails postoperative adrenal failure. Autonomous hormone secretion can be expected in >80% of patients with ACC. However, routine use of the recently introduced urine steroid metabolomic analysis (40) might further increase this number and may serve as a fingerprint of the tumor, facilitating early detection of recurrence. In turn, there is a high likelihood that a large adrenal mass is not an ACC if autonomous steroid secretion is absent.

Imaging

Together with a careful endocrine workup, modern cross-sectional imaging is able to correctly diagnose an adrenal mass as ACC before surgery in most cases. Size is an obvious criterion to differentiate an adrenal mass because the median size of ACCs is >11 cm, whereas most adenomas are <5 cm. Tumors between 3 and 10 cm may be diagnostically challenging. Currently, no single imaging method can characterize with certainty a localized adrenal mass as ACC, but many studies in the last 15 years have established a threshold of ≤ 10 Hounsfield units (HU) in unenhanced computed tomography (CT) for the diagnosis of a benign adrenal lesion (for review, see Refs. 41 and 42). Because all series included only a few ACCs, we have now confirmed in 51 ACC cases that none had a density of less than 13 HU (43). However, CT with delayed contrast media washout using a cutoff of 50% washout and an absolute value of >35 HU after 10–15 minutes has superior diagnostic accuracy (44–47). State-of-the-art magnetic resonance imaging (MRI) including chemical shift and washout analysis is probably equally accurate, but the number of published studies is smaller (41, 42). In our experience, it is easier to obtain a standardized CT scan than an optimal MRI. Furthermore, preoperative CT can be easily combined with chest imaging for the presence of metastatic disease. Thus, we usually recommend CT if pregnancy can be excluded.

Ultrasound techniques (including contrast-enhanced methods) have not been thoroughly investigated but may be particularly valuable for the detection of liver metastases and during follow-up in selected patients (48).

In the difficult case, additional functional imaging is often helpful. With virtually no exception, ACCs have a high ^{18}F -fluorodeoxyglucose uptake; however, this is also the case for most adrenal metastases, pheochromocytomas, and even some adenomas (49, 50). The adrenocortical origin of a lesion may be proven using metomidate tracers, which specifically bind to adrenocortical CYP11B enzymes, which catalyze the final steps of steroid synthesis (51). Thus, the specificity of this still experimental method is high, but recent data suggest that the sensitivity in ACC is lower than in adenomas (52).

All patients with suspected ACC require a chest CT scan for pulmonary metastases before surgery, which unfortunately is often neglected. Specific imaging of brain and bones is only needed in case of clinical suspicion. There is some evidence that 18F-fluorodeoxyglucose-positron emission tomography/CT might improve staging of the patients at initial diagnosis or during follow-up (50, 53, 54).

Biopsy of an adrenal mass is usually not helpful

In our experience, there is almost no role for a fine-needle biopsy in the diagnostic workup of an adrenal tumor because the diagnostic accuracy is often low (55) and violation of the tumor capsule may promote needle track metastases. The only two scenarios with a potential benefit comprise: 1) the few patients with metastatic disease not scheduled for surgery, in which other methods (eg, endocrine workup, metomidate imaging) have failed to establish the diagnosis; and 2) patients with a suspicious endocrine-inactive adrenal mass and a history of extra-adrenal malignancy, in whom the result would affect treatment.

Follow-up investigations

Recurrence is a frequent event even after complete resection, and the time to recurrence influences treatment decisions (see Recurrent ACC). Therefore, we recommend imaging every 3 months (CT of the chest and CT/MRI of abdomen) together with monitoring of steroid hormones initially found to be secreted by the tumor. After the first 2 years of follow-up, we gradually increase imaging intervals. However, we recommend follow-up in patients without evidence of disease for a minimum of 10 years after surgery. In patients with advanced disease, imaging intervals are guided by the treatment protocol.

Areas of uncertainty: diagnostic workup

- Will the urinary gas chromatography-mass spectrometry steroid profile prove to be of superior diagnostic accuracy at initial diagnosis and during follow-up?
- The best methods, time intervals of tumor evaluation, and the optimum duration of follow-up have never been studied.

Histopathological diagnosis

The histopathological diagnosis of adrenal tumors remains challenging; eg, the rate of incorrect initial histopathological diagnosis in Germany was 13% (56). Two major problems need to be addressed. First, the adrenocortical origin of the mass must be established. Here expression of SF1 has emerged as the most valid marker (18, 21, 57). Second, the discrimination of benign from ma-

lignant adrenocortical tumors requires the evaluation of multiple parameters. The Weiss score (58) is still the best-validated score and should be used for this purpose. Unfortunately, interobserver variability is rather high. A simplified score together with a structured training program may improve the reproducibility of the pathological diagnosis in the future (59–62). In addition, two large ENSAT studies demonstrated that the quantification of the proliferation marker Ki67 is highly important because Ki67 is the most powerful prognostic marker in both localized and advanced ACC (63, 64) to guide treatment decisions.

Staging and prognosis

Consensus has been obtained during the last 4 years that the tumor-staging classification suggested by ENSAT, which is a modification of the Lee classification from 1995, reliably predicts the outcome of patients (65, 66). In this staging system, stage 1 and stage 2 are defined as strictly localized tumors with a size of ≤ 5 cm or > 5 cm, respectively. Stage 3 tumors are characterized by infiltration in surrounding tissue, positive regional lymph nodes, or a tumor thrombus in the vena cava/renal vein. Stage 4 is restricted to patients with distant metastasis. Although this staging system can differentiate patient cohorts with different prognosis and a 5-year stage-dependent survival of 81, 61, 50, and 13% (65), there is a need for further improvements; eg, by adding a grading system (63, 67). Molecular markers like matrix metalloproteinase type 2 (68), glucose transporter GLUT1 (69), SF1 (18), BUB1B and PINK1 (26) might help in the future, but none of them is yet validated.

Treatment

With the exception of one trial (70), treatment of ACC is based on nonrandomized trials or retrospective analyses. Therefore, the level of evidence for most recommendation is class II–IV. Whenever possible, patients should be treated within clinical trials (www.clinicaltrials.gov).

In all tumor stages, the adrenotoxic drug mitotane is of paramount importance and therefore is discussed separately.

ACC amenable to radical resection (Figure 1A)

Surgery is the single most important intervention in the treatment of nonmetastatic ACC. During the last 5 years there has been a lively debate on the best surgical approach to localized ACC. Although preoperative evidence of locally advanced disease undoubtedly requires open adrenalectomy, some groups have postulated that tumors with a diameter of < 10 cm may be safely treated by laparoscopic adrenalectomy, whereas others are convinced that

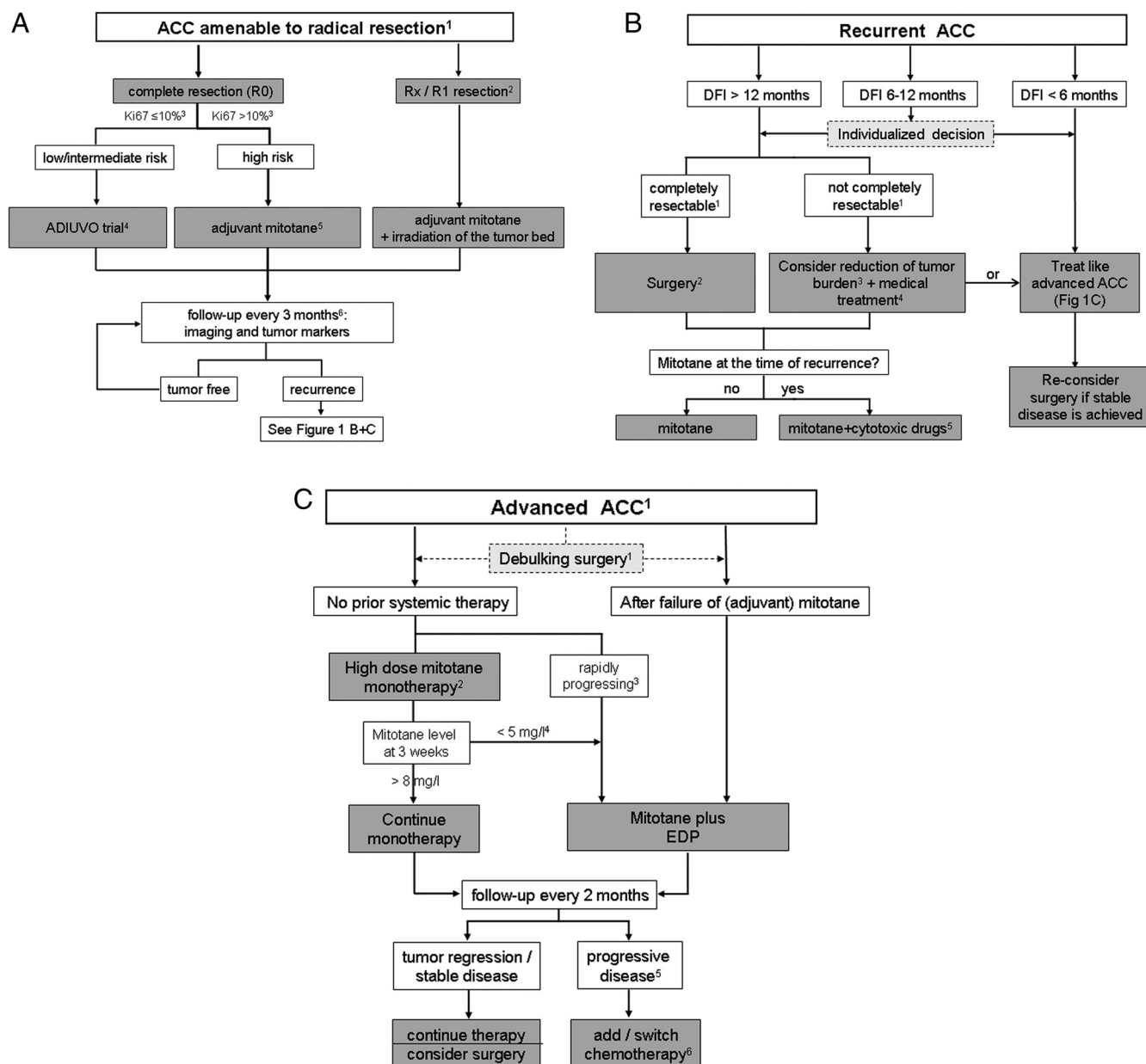


Figure 1. Treatment flow charts for patients with adrenocortical carcinoma. Consider always enrollment of patients in a clinical trial (for an updated list see www.clinicaltrials.gov). A, ACC amenable to radical resection. ¹ All patients with stages I+II and most patients with stage III should be amenable to radical resection. If complete resection is not feasible, consider neoadjuvant treatment (eg, mitotane + cisplatin or EDP). In selected patients with single metastases, complete resection might be possible as well. ² In patients with R2 resection, consider resurgery by an expert surgeon or see Figure 1C. ³ If Ki67 staining is not available, a high proliferative index (>5 mitoses/50 high-power fields) may be used for risk stratification. Patients with stage IV are judged as high-risk patients independent of Ki67. ⁴ www.adiuvo-trial.org. If inclusion is not possible, decide individually between observation only or adjuvant mitotane. ⁵ In some patients (eg, Ki67 $\geq 30\%$ or large tumor thrombus in the vena cava), we consider additional cytotoxic therapy (eg, three cycles of cisplatin 80 mg/m²). ⁶ After 2 years, the time intervals are gradually extended. B, Recurrent ACC. Disease-free interval (DFI) is defined as time elapsed between initial surgery and date of recurrence. ¹ To be judged by an expert multidisciplinary team, ² or alternatively other local measures like radiofrequency ablation or chemoembolization, ³ by surgery or other local measures like radiofrequency ablation or chemoembolization, ⁴ even in case of mitotane naive, postinterventionally combined treatment with mitotane + cisplatin should be considered; ⁵ eg, three cycles of cisplatin (80 mg/m²) every 3 weeks. C, Advanced ACC. ¹ Only in selected patients (eg, with severe hormone excess). ² Alternatively, patients could be treated with an experimental therapy within a prospective clinical trial; ³ by clinical judgment: eg, rapidly progressing symptoms within <3 months, recurrence within 6 months after radical surgery, involvement of >2 organs, or Ki67 $>30\%$. ⁴ If mitotane concentration at 3–4 weeks is <5 mg/L, consider adding EDP without delay because it is unlikely that this patient will reach a level >14 mg/L within the first 12 weeks of treatment. ⁵ In case of severe localized symptoms, consider local treatment like radiotherapy. ⁶ For the best currently available cytotoxic regimens see Supplemental Table 1 (published on The Endocrine Society's Journals Online web site at <http://jcem.endojournals.org>) and contact specialized center. Rx, resection with uncertain margins; R1, incomplete resection with microscopically positive margins; R2, incomplete resection with macroscopically positive margins; DFI, disease-free interval.

this carries an increased risk for recurrence. Because all studies are retrospective and methodologically disputable (71–75), no final conclusion can be drawn (76, 77). Open adrenalectomy should still be regarded as standard treatment for ACC, and laparoscopic surgery should be performed within a clinical trial or at least as part of an observational study.

More importantly, the extent of local resection and the experience of the surgeon may be key variables for the long-term outcome of surgery. Although no standard has been established concerning the extent of the first operation (78), the results of a recent retrospective analysis of 283 patients with stage I–III ACC suggest that locoregional lymph node dissection (LND) might improve both diagnostic accuracy and therapeutic outcome (79). In multivariate analyses, we found a significantly reduced risk for tumor recurrence (hazard ratio [HR], 0.65) and disease-related death (HR, 0.54) in LND patients when compared with no-LND patients. On the other hand, there seems to be little benefit of systematic ipsilateral nephrectomy in the absence of gross local invasion (80). However, to achieve a complete resection (R0 resection), locally involved organs or large veins should be resected en bloc, including tumor thrombus embolectomy (81, 82).

Irrespective of the surgical approach, we strongly recommend that surgery for ACC should be performed by a surgeon with long-standing experience in adrenal surgery. Although we acknowledge that there is no consensus about what qualifies an expert ACC surgeon, we propose—based on recent data (83, 84) and personal experience—that surgery for suspected ACC should be limited to surgeons with >20 adrenalectomies per year.

Adjuvant therapy

Although the natural rate of recurrence is uncertain (85, 86), there is no doubt that an effective adjuvant treatment would be of great benefit. The treatment modalities currently considered include mitotane, irradiation of the tumor bed, cytotoxic agents, or combinations of them. All available data are retrospective, but the most convincing results derive from a large retrospective analysis by Terzolo et al (87). In comparison to two independent control groups, patients with adjuvant mitotane had a significantly improved recurrence-free and overall survival (42 months vs 10 and 25 months, and 110 months vs 52 and 67 months, respectively). Nonetheless, it remains a matter of discussion, whether adjuvant mitotane is of long-term benefit for all patients (88, 89). This is particularly true for patients with presumably low or intermediate risk of recurrence, eg, defined by R0 resection, absence of metastases, and a Ki67 $\leq 10\%$ (90). For this group of patients, we recommend inclusion in the international randomized

ADIUVO trial (www.adiuvo-trial.org) comparing mitotane with a strategy of watchful waiting.

External beam radiation therapy of the tumor bed might be a means to lower the high incidence of local recurrence. Currently there are three retrospective studies with 14, 10, and 16 patients plus corresponding controls, of which the first two showed a benefit in preventing local recurrence (91–93). None of them demonstrated an advantage for overall survival. Therefore, we currently recommend adjuvant radiotherapy only in case of particularly high risk for local recurrence, eg, R1 resection.

Data on adjuvant cytotoxic chemotherapy are scarce. The only study dates back to 2000 and investigated 17 patients treated with streptozotocin plus mitotane (94). In this nonrandomized study, it remained uncertain whether the positive effects were related to mitotane, streptozotocin, or the combination of both drugs. Other cytotoxic drugs have not been investigated in adult ACC in this setting, although we believe that a platinum-based adjuvant therapy might be of benefit for patients at very high risk of recurrence.

Based on the available data, we currently stratify patients according to their perceived risk of recurrence. Recent data from the ENSAT ACC study group indicate that resection status and Ki67 index are the most relevant prognostic parameters. As shown in Figure 1A, we define three risk groups and recommend treatment as indicated. In selected patients with very high risk, we consider additional treatment options. For instance, we would offer a patient with Ki67 >30% and a large tumor thrombus in the vena cava a combination therapy of mitotane and three cycles of cisplatin (eg, 80 mg/m²).

Areas of uncertainty: localized disease

- Is clinical outcome in expert centers with >20 adrenalectomies per year superior compared to smaller centers?
- Is outcome after laparoscopic surgery comparable to open surgery in stage I–II ACC?
- Is LND required in all patients with suspected ACC?
- Is a combined adjuvant treatment (eg, mitotane + cisplatin) of benefit in a subset of high-risk patients?

Recurrent ACC (Figure 1B)

Although ACC recurrence is frequent, few data exist on the optimal management of recurrent ACC. Three recent papers describe the experience with chemoembolization, radiofrequency ablation, and surgical resection for liver metastases (80, 95, 96). Although all but one of these 76 patients experienced secondary recurrence, individual patients took advantage from these procedures. In 2011, two groups reported their results on pulmonary resection for

metastatic ACC in 24 and 26 patients (97, 98) and came to similar conclusions: pulmonary surgery might be useful in selected patients (eg, young patients with slowly progressing disease) because long-term disease control can be achieved in a subset of patients.

Based on the results of two recent studies in 45 and 154 patients with first recurrence (99, 100), we suggest the following approach (Figure 1B): surgery for recurrent ACC should be performed in patients with a disease-free interval of more than 12 months, in whom a complete resection is feasible. However, we advocate against surgery if the time between surgery and recurrence is less than 6 months. These patients are likely to benefit more from aggressive medical treatment. In all other patients, an individualized decision is required, and they may be candidates for a combined approach of medical therapy and ablative procedures.

Advanced disease (Figure 1C)

All patients not qualifying for a localized treatment who are in acceptable clinical condition require systemic therapy (for the best currently available regimens see Supplemental Table 1). Although there is significant heterogeneity even in advanced ACC (101, 102), the disease has a strong tendency toward rapid progression, and a stabilization for more than 3 months is a rare exception. The median survival in these patients in most series is about 12 months.

The only approved drug in advanced ACC is mitotane. Despite the lack of prospective, controlled trials, mitotane was already approved in the United States in 1970 and in Europe in 2004. Most data derive from retrospective series, and the objective response rate is at best 24% (103). Many years ago, the concept of targeting a certain mitotane plasma level was introduced (104, 105), and recently another retrospective study provided evidence that reaching a mitotane plasma level >14 mg/L is associated with improved overall survival (106).

Only the combination chemotherapy of etoposide, doxorubicin, cisplatin and mitotane (EDP-M) has been validated in a randomized controlled trial. This FIRM-ACT (First International Randomized trial in locally advanced and Metastatic Adrenocortical Carcinoma Treatment) trial included a total of 304 patients and compared EDP-M with streptozotocin and mitotane (Sz-M), both as first- and second-line cytotoxic treatment. Although overall survival was not significantly different (14.8 months, EDP-M; 12.0 months, Sz-M; HR, 0.79; $P = .07$), objective response rate and progression-free survival clearly favored EDP-M (23.2 vs 9.2%, $P < .001$; and 5.0 vs 2.1 months; HR, 0.55; $P < .001$). Furthermore, EDP-M was similarly effective in second-line therapy in patients failing Sz-M as

first-line treatment. Therefore, it is tempting to speculate that the crossover design of the study attenuated the survival benefit of EDP-M. Due to these data and the fact that the rate of serious adverse events and quality of life during the treatment were comparable between the groups, most experts now advocate EDP-M as first-line therapy for patients requiring cytotoxic treatment (39, 107, 108).

However, the observation that EDP-M is similarly successful in first- and second-line therapy leads us to two main additional conclusions. 1) Based on a study by Assié et al (101), we select patients with presumably less aggressive disease (eg, slowly progressing tumor growth, only two involved organs, long disease-free interval after initial surgery) and treat them with mitotane monotherapy (Figure 1C). Based on a study by Mauclère-Denost et al (109), we increase the mitotane dosage within a few days to 6 g/d. We continue mitotane as monotherapy in patients with a mitotane concentration >8 mg/L after 3–4 weeks of treatment, and in patients with a blood level <5 mg/L we usually add EDP because the likelihood to reach a blood level >14 mg/L in a reasonable time frame is extremely low (110). In all other patients, we decide individually based on tolerability of mitotane and the clinical condition of the patient. 2) We believe that the FIRM-ACT results justify testing of new drugs as first-line treatment in selected patients with a presumed life expectancy of >6 months, allowing them to receive EDP-M in case of progression at first tumor evaluation. This concerns particularly targeted therapies because mitotane might diminish their antitumor efficacy by enhanced drug metabolism (111) (see also Mitotane: mechanism of action, pharmacokinetics, and management).

For patients failing EDP-M, only a limited number of regimens has been investigated. One is Sz-M (investigated as part of the FIRM-ACT study), but only about 15% of patients showed at least a stabilization for >6 months during this second-line treatment (M. Fassnacht, H. H. Mueller, B. Skogseid, unpublished data). Therefore, we currently offer our patients in this situation the combination of gemcitabine and capecitabine. As second-line chemotherapy, this combination achieved disease stabilization for at least 6 months in 8 of 28 patients (29%) (112). In patients with painful skeletal metastases, palliative radiotherapy is often of benefit (113). When the disease has progressed despite different cytotoxic treatments and a mitotane level >14 mg/L, it might be reasonable to stop mitotane to reduce the problem of drug interaction for subsequent therapies.

In case a given therapy is able to stabilize a progressive disease for at least 4 months, we reconsider surgery or other locoregional approaches.

Table 2. Published Experience With Targeted Therapies^a

Agents	Rationale	n	Outcome	Ref.
Sunitinib	Multi-TKI (VEGFR, PDGFR β , c-kit, FLT3, RET)	35	5 stable disease	111
Cixutumumab + temsirolimus	IGF-1R antibody + mTOR inhibitor	26	11 stable disease	122
Gefitinib	Inhibition of EGFR signaling	19	No response	114 ^b
Dovitinib	Multi-TKI (FGFR, PDGFR, VEGFR)	17	4 stable disease	121 ^b
Bevacizumab + capecitabine	Inhibition of VEGF signaling + cytotoxic drug	10	No response	119
Erlotinib + gemcitabine	Inhibition of EGFR signaling + cytotoxic drug	10	1 stable disease	115
Sorafenib + paclitaxel	Multi-TKI (BRAF, VEGFR, c-kit, PDGFR β) + cytotoxic drug	9	No response	120
Imatinib	Inhibition of c-KIT and PDGF	4	No response	140
Everolimus	mTOR inhibitor	4	No response	123

^a Only studies reporting at least three patients have been included.

^b Published only as abstract.

Areas of uncertainty: recurrent and advanced disease

- Is surgery of the primary tumor or debulking surgery in general of benefit or harm in patients with metastatic ACC?
- Which patients are candidates for mitotane monotherapy?
- For which combination therapies is concomitant mitotane beneficial?
- When should mitotane treatment be stopped in progressing disease?

Targeted therapies and salvage treatment

Current treatment concepts fail in many patients with advanced ACC. This stimulated interest in molecular-targeted therapies (Table 2). The first trials targeted the epidermal growth factor receptor, but both gefitinib (114) and the combination of erlotinib and gemcitabine (115) did not lead to promising results.

Targeting of tumor vasculature has attracted more attention in ACC because vascular endothelial growth factor (VEGF) and its receptor VEGF-R2 have been demonstrated to be highly expressed in ACC (116), and antiangiogenic drugs exhibited modest antitumor effects in preclinical tumor models (117, 118). However, bevacizumab, a humanized anti-VEGF monoclonal antibody, in combination with capecitabine did not yield any tumor response (n = 10) (119). Similarly, the multi-tyrosine kinase inhibitor (TKI) sorafenib in combination with paclitaxel failed to demonstrate clinical efficacy in nine ACC patients (120).

Among the VEGF-targeting TKIs, only sunitinib has demonstrated modest antitumor effects in a phase II clinical trial (111). The primary endpoint of progression-free survival at 12 weeks was met by five patients (14.3%). In this trial, we confirmed that concomitant mitotane treatment strongly diminished plasma levels of sunitinib and its active metabolite. Therefore, one of the main lessons from this trial is that sunitinib and other multi-TKI should preferentially be

administered in patients without mitotane pretreatment or with dose adjustments of the respective TKIs.

Preliminary results have been reported during the 2013 ASCO meeting for the multi-TKI dovitinib (NCT01514526). Disease stabilization >6 months has been observed in 23% of 17 ACC patients (121).

Only recently drugs targeting IGF-2, the most up-regulated gene in ACC, and its receptor IGF-1R became clinically available. Activity of IGF-1R antagonists has been demonstrated in vitro and in a xenograft model of ACC (11). Results of phase I trials with the highly specific IGF-1R inhibitor linsitinib (OSI-906) were promising and led to the first industry-sponsored, randomized, placebo-controlled, double-blind phase III clinical trial in ACC (GALACCTIC, NCT00924989). A total of 138 patients have been enrolled, and results are expected to be published by 2014.

In an extended phase I trial with the IGF-1R antibody cixutumumab in combination with temsirolimus, an inhibitor of mammalian target of rapamycin (mTOR), one of the downstream targets of IGF-1R signaling, 26 patients with advanced ACC have been treated. In 11 of these patients (42%), disease stabilization for 6 months or longer has been observed (122). However, targeting mTOR alone using everolimus resulted in no meaningful response in four patients (123).

Overall, it appears that using only one drug may not suffice to induce an objective response. Although enthusiasm toward IGF-1R antagonists in general has markedly decreased, we—not only due to impressive tumor responses in individual patients—still believe that ACC is a malignancy in which this class of drugs, probably in combination with other drugs, holds therapeutic potential.

Our group has recently developed a radionuclide therapy based on [¹³¹I]iodometomidate, and we have applied this method on a compassionate-use basis in 11 patients with advanced, progressing ACC (124). In one patient, a decrease of tumor burden of some 50% lasting for 26 months has been demonstrated, and five additional pa-

tients experienced stable disease, lasting in three for at least 10 months.

All other targeted treatment approaches are still in a preclinical stage. From our perspective, the following concepts merit further investigations: inhibition of heat shock protein 90 (125), the proteasome inhibitor bortezomib (126), and targeting SF1 (22).

Other salvage therapies are based primarily on small series like oral etoposide and oral cyclophosphamide (127) or case reports (128, 129).

Overall, the poor efficacy of several classes of targeted therapies has markedly dampened expectations of ACC tumor control in metastatic disease.

Mitotane: mechanism of action, pharmacokinetics and management

As described in the sections Adjuvant therapy and Advanced ACC, mitotane is currently the cornerstone of medical treatment for ACC. It is given orally in 500-mg tablets (Lysodren; HRA Pharma Paris, Bristol-Myers Squibb). De-

Table 3. Recommendations on Mitotane Management

Parameter		Recommendations
Initiation of treatment		Optimal distribution of mitotane during the day has not been studied; thus we respect patient preference.
High-dose regime	Preferred regimen for monotherapy.	Start with 1.5 g/d and increase within 4–6 d to 6 g/d. Adapt dose according plasma levels (maximum dose 12 g/d, but most patients do not tolerate >8 g/d).
Low-dose regime	For patients with reduced clinical conditions and in combination therapy.	Start with 1 g/d and increase within 1 wk to 3 g/d mitotane daily dose. Adapt dose according plasma levels.
Drug monitoring		
Mitotane plasma level		Check every 3–4 wk during the first 6 months, then intervals might be prolonged.
Target plasma level		14–20 mg/L; in patients without adverse effects plasma levels >20 mg/L can be accepted.
Safety parameters		
GOT, GPT, bilirubin (GGT)	GGT is invariably elevated without clinical consequences.	Check initially every 3–4 wk, after 6 months every 8 wk. If GPT/GPT increase >3-fold ULN, interrupt mitotane treatment.
Blood count	Bone marrow toxicity is rare, but agranulocytosis might be life-threatening.	Check for relevant leukopenia, thrombocytopenia, and anemia (rare) initially after 3–4 wk, then every 3–4 months.
Cholesterol (HDL, LDL), triglycerides	Lipid alterations occur frequently.	In adjuvant setting, check every 3–4 months. If LDL/HDL ↑↑, consider treatment with rosuvastatin or pravastatin.
Hormonal changes and hormone replacement		
Glucocorticoids	Due to accelerated metabolism (CYP3A4 induction) and increased cortisol-binding globulin, a high hydrocortisone replacement dosage is required (in the long run, average dosage 40–60 mg/d).	We start usually with 20 mg/d hydrocortisone and taper dosage according clinical signs. Plasma ACTH is probably the best of poor monitoring parameters and should be in the upper normal range or slightly above.
Mineralocorticoids	Replacement is needed only in a subset of patients.	Check renin every 3–6 months and treat with fludrocortisone according to renin concentration and blood pressure.
Androgens	Due to CYP3A4 induction, increased SHBG, and inhibition of 5- α reductase, hypogonadism is frequent (but clinically variable).	Difficult to diagnose without measuring dihydrotestosterone. Replacement with dihydrotestosterone may be individually considered.
Oral contraception	CYP3A4 induction leads to increased clearance and reduced efficacy (and estrogens might play a role in ACC tumorigenesis).	Use mechanical contraception.
Thyroid hormones	Alternations of thyroid hormones are frequent, but variable (and not yet fully elucidated).	Check TSH, free T ₃ , free T ₄ every 3–4 months. Replacement with levothyroxine in case of hypothyroidism.
Selection of other relevant drug interactions	Examples of drugs metabolized by CYP3A4.	
Hypertension	Calcium antagonists	Use instead ACE inhibitors, β -blockers, α -blockers, angiotensin 2-antagonists, diuretics.
Hypercholesterolemia	Most HMG-coA reductase inhibitors (eg, atorvastatin, cerivastatin, lovastatin, simvastatin).	Use pravastatin or rosuvastatin.
Insomnia, agitation	Benzodiazepines (eg, midazolam, diazepam), Z-drugs (eg, zopiclone, zolpidem).	For many cases, no alternatives are available. Consider increased dosage.
Infection	Some macrolide antibiotics (eg, erythromycin, clarithromycin).	Use alternative antibiotics like azithromycin, moxifloxacin, ciprofloxacin.
Analgesia	Some opioids (eg, fentanyl, methadone, oxycodone, tramadol).	Use instead morphine or hydromorphone.

GOT, glutamic oxaloacetic transaminase; GPT, glutamic pyruvic transaminase; GGT, γ -glutamyl transpeptidase; HDL, high-density lipoprotein; LDL, low-density lipoprotein; ULN, upper limit of normal; ACE, angiotensin-converting-enzyme; HMG-coA, 3-hydroxy-3-methylglutaryl-coenzyme A.

spite its use for more than 50 years, little is known about the molecular mechanism of mitotane action, and some observations, such as binding of mitotane to a protein receptor, have not been conclusively confirmed. Recent data suggest that down-regulation of mitochondrial respiratory chain is involved (130, 131), but the pathway leading to these changes has not been clarified, even using high-throughput techniques such as gene expression microarrays and proteome profiling (30, 132, 133).

Like the mechanism of action, pharmacokinetic data are limited. Nested in the FIRM-ACT trial, a study on the pharmacokinetics of mitotane investigated the relationship between mitotane dose and plasma concentration comparing two dosing regimens (110). Surprisingly, a “high-dose starting regimen” only led to a small, nonsignificant difference in mitotane levels with a similar rate of adverse events. Only among patients not receiving concomitant cytotoxic treatment was a clear trend toward higher mitotane exposure in the high-dose group (area under the curve 0–12 weeks: 1013 vs 555 mg per d/L; $P = .080$). However, the variability of individual plasma levels reached by a given dosage is high, and it remains unclear which enzymes metabolize mitotane in humans, although there is first evidence that CYP2B6 might be involved (134). Several studies have demonstrated that a mitotane plasma level >14 mg/L is required for clinical efficacy of the drug (104–106), making regular monitoring of the drug level mandatory. Of note, this concept has also been introduced very recently in the adjuvant setting (135).

The recent observation of a strong and sustained induction of cytochrome P450 3A4 (CYP3A4) by mitotane (136) has now been confirmed using a steroidomics approach (137). The induction of CYP3A4 has a major impact on the care of ACC patients because mitotane is one of the strongest CYP3A4 inducers, lowering the blood levels of many drugs frequently coadministered with mitotane (including but not limited to steroids, antihypertensives, and antibiotics) (138). A list of drugs with a high potential of interaction is nested in Table 3.

Mitotane comes with significant toxicity, and patients should be monitored closely by an experienced physician. The incidence and severity of adverse drug effects have only been systematically evaluated in a few cohorts (109, 110, 139). However, dizziness, vertigo, and other central nervous system disturbances are common, and virtually all patients suffer some kind of gastrointestinal symptoms requiring active management with antiemetics and loperamide as individually indicated. Although grade 3/4 toxicity is overall rare, we have seen life-threatening agranulocytosis and liver failure in single patients. In contrast, in virtually all patients, a strong elevation of the γ -glutamyltransferase is detectable, which in our view is clinically

not relevant. Furthermore, all patients develop adrenal insufficiency, which has to be replaced with a high dosage of hydrocortisone (due to the induction of CYP3A4 with increased metabolism of cortisol and increased cortisol-binding globulin).

Areas of uncertainty: targeted therapy and mitotane management

- Which combinations of molecular-targeted drugs are most useful to combat advanced ACC?
- Which drugs could be usefully combined with mitotane despite mitotane-induced CYP3A4 activity?
- Are there means to reduce mitotane-induced CYP3A4 activity?

Future Perspectives

Despite advances in the molecular pathogenesis of ACC, the initiating and driving mutations remain incompletely understood, but are of key importance for the development of better treatments. Here international efforts are under way to provide a comprehensive molecular analysis including whole genome sequencing in a large number of ACC cases. Urinary steroid profiling seems to be a promising diagnostic tool; however, its true value has to be demonstrated in large-scale prospective, multicenter trials. Concerning surgery, the time has come for randomized trials to assess the best operation strategy (eg, with or without LND). We expect that the ADIUVO trial will shed further light on the value of adjuvant mitotane in ACC. A better understanding of the molecular action of mitotane is urgently needed now to allow prediction of the individual response to this difficult drug and as a prerequisite for the development of less toxic compounds. Although targeted therapies have been largely disappointing in advanced ACC, this may be in part related to insufficient drug levels due to concomitant or previous mitotane administration and to the fact that they were mostly studied as salvage therapy in refractory disease. The occasional impressive response to inhibition of IGF-1 signaling indicates its therapeutic potential, but it probably needs to be combined with other drugs for optimum activity. Furthermore, earlier use of targeted therapies might lead to improved results without jeopardizing the efficacy of later cytotoxic therapy. Currently, only four intervention trials are recruiting patients (NCT01832974, NCT01048892, NCT00777244, and NCT01898715). Therefore, it is the task of the ACC community to convince public stakeholders and pharmaceutical companies to make a stronger commitment for clinical trials in ACC. However, the highly successful international cooperation in the fight

against this dreadful disease that was triggered by the EN-SAT and the FIRM-ACT consortium has undoubtedly set the stage for major progress in the coming decade.

Acknowledgments

Address all correspondence and requests for reprints to: Prof Dr Martin Fassnacht, Department of Internal Medicine IV, Hospital of the University of Munich, Ziemssenstrasse 1, 80336 München, Germany. E-mail: martin.fassnacht@med.uni-muenchen.de.

This work was supported by Deutsche Forschungsgemeinschaft Grants FA 466/4-1 (to M.F.) and KR 4371/1-1 (to M.K.) and the European Union (Seventh Framework Programme [FP7/2007–2013] under Grant Agreement 259735) (to M.F. and B.A.).

Disclosure Summary: The authors received support for a clinical trial from Pfizer Pharma and participated in a pharmacokinetic trial on mitotane sponsored by HRA Pharma and a trial on OSI-906 sponsored by Astellas Pharma.

References

- Allolio B, Fassnacht M. Clinical review: adrenocortical carcinoma: clinical update. *J Clin Endocrinol Metab.* 2006;91:2027–2037.
- Kebebew E, Reiff E, Duh QY, Clark OH, McMillan A. Extent of disease at presentation and outcome for adrenocortical carcinoma: have we made progress? *World J Surg.* 2006;30:872–878.
- Kerkhofs TM, Verhoeven RH, Van der Zwan JM, et al. Adrenocortical carcinoma: a population-based study on incidence and survival in the Netherlands since 1993. *Eur J Cancer.* 2013;49:2579–2586.
- Custódio G, Komechen H, Figueiredo FR, Fachin ND, Pianovski MA, Figueiredo BC. Molecular epidemiology of adrenocortical tumors in southern Brazil. *Mol Cell Endocrinol.* 2012;351:44–51.
- Giordano TJ, Thomas DG, Kuick R, et al. Distinct transcriptional profiles of adrenocortical tumors uncovered by DNA microarray analysis. *Am J Pathol.* 2003;162:521–531.
- de Fraipont F, El Atifi M, Cherradi N, et al. Gene expression profiling of human adrenocortical tumors using complementary deoxyribonucleic acid microarrays identifies several candidate genes as markers of malignancy. *J Clin Endocrinol Metab.* 2005;90:1819–1829.
- Gicquel C, Bertagna X, Gaston V, et al. Molecular markers and long-term recurrences in a large cohort of patients with sporadic adrenocortical tumors. *Cancer Res.* 2001;61:6762–6767.
- Berthon A, Sahut-Barnola I, Lambert-Langlais S, et al. Constitutive β -catenin activation induces adrenal hyperplasia and promotes adrenal cancer development. *Hum Mol Genet.* 2010;19:1561–1576.
- Gaujoux S, Grabar S, Fassnacht M, et al. β -Catenin activation is associated with specific clinical and pathologic characteristics and a poor outcome in adrenocortical carcinoma. *Clin Cancer Res.* 2011;17:328–336.
- Gicquel C, Bertagna X, Schneid H, et al. Rearrangements at the 11p15 locus and overexpression of insulin-like growth factor-II gene in sporadic adrenocortical tumors. *J Clin Endocrinol Metab.* 1994;78:1444–1453.
- Barlaskar FM, Spalding AC, Heaton JH, et al. Preclinical targeting of the type I insulin-like growth factor receptor in adrenocortical carcinoma. *J Clin Endocrinol Metab.* 2009;94:204–212.
- Tissier F, Cavard C, Groussin L, et al. Mutations of β -catenin in adrenocortical tumors: activation of the Wnt signaling pathway is a frequent event in both benign and malignant adrenocortical tumors. *Cancer Res.* 2005;65:7622–7627.
- Ragazzon B, Libé R, Gaujoux S, et al. Transcriptome analysis reveals that p53 and β -catenin alterations occur in a group of aggressive adrenocortical cancers. *Cancer Res.* 2010;70:8276–8281.
- Gaujoux S, Tissier F, Groussin L, et al. Wnt/ β -catenin and 3',5'-cyclic adenosine 5'-monophosphate/protein kinase A signaling pathways alterations and somatic β -catenin gene mutations in the progression of adrenocortical tumors. *J Clin Endocrinol Metab.* 2008;93:4135–4140.
- Bonnet S, Gaujoux S, Launay P, et al. Wnt/ β -catenin pathway activation in adrenocortical adenomas is frequently due to somatic CTNNB1-activating mutations, which are associated with larger and nonsecreting tumors: a study in cortisol-secreting and -nonsecreting tumors. *J Clin Endocrinol Metab.* 2011;96:E419–E426.
- Heaton JH, Wood MA, Kim AC, et al. Progression to adrenocortical tumorigenesis in mice and humans through insulin-like growth factor 2 and β -catenin. *Am J Pathol.* 2012;181:1017–1033.
- Drelon C, Berthon A, Ragazzon B, et al. Analysis of the role of Igf2 in adrenal tumour development in transgenic mouse models. *PLoS One.* 2012;7:e44171.
- Sbiera S, Schull S, Assie G, et al. High diagnostic and prognostic value of steroidogenic factor-1 expression in adrenal tumors. *J Clin Endocrinol Metab.* 2010;95:E161–E171.
- Almeida MQ, Soares IC, Ribeiro TC, et al. Steroidogenic factor 1 overexpression and gene amplification are more frequent in adrenocortical tumors from children than from adults. *J Clin Endocrinol Metab.* 2010;95:1458–1462.
- Lalli E. Adrenocortical development and cancer: focus on SF-1. *J Mol Endocrinol.* 2010;44:301–307.
- Duregon E, Volante M, Giorcelli J, Terzolo M, Lalli E, Papotti M. Diagnostic and prognostic role of steroidogenic factor 1 in adrenocortical carcinoma: a validation study focusing on clinical and pathologic correlates. *Hum Pathol.* 2013;44:822–828.
- Doghman M, Cazareth J, Douguet D, Madoux F, Hodder P, Lalli E. Inhibition of adrenocortical carcinoma cell proliferation by steroidogenic factor-1 inverse agonists. *J Clin Endocrinol Metab.* 2009;94:2178–2183.
- Herrmann LJ, Heinze B, Fassnacht M, et al. TP53 germline mutations in adult patients with adrenocortical carcinoma. *J Clin Endocrinol Metab.* 2012;97:E476–E485.
- Raymond VM, Else T, Everett JN, Long JM, Gruber SB, Hammer GD. Prevalence of germline TP53 mutations in a prospective series of unselected patients with adrenocortical carcinoma. *J Clin Endocrinol Metab.* 2013;98:E119–E125.
- Raymond VM, Everett JN, Furtado LV, et al. Adrenocortical carcinoma is a lynch syndrome-associated cancer. *J Clin Oncol.* 2013;31:3012–3018.
- de Reyniès A, Assié G, Rickman DS, et al. Gene expression profiling reveals a new classification of adrenocortical tumors and identifies molecular predictors of malignancy and survival. *J Clin Oncol.* 2009;27:1108–1115.
- Giordano TJ, Kuick R, Else T, et al. Molecular classification and prognostication of adrenocortical tumors by transcriptome profiling. *Clin Cancer Res.* 2009;15:668–676.
- Simon DP, Giordano TJ, Hammer GD. Upregulated JAG1 enhances cell proliferation in adrenocortical carcinoma. *Clin Cancer Res.* 2012;18:2452–2464.
- Tömböl Z, Szabó PM, Molnár V, et al. Integrative molecular bioinformatics study of human adrenocortical tumors: microRNA, tissue-specific target prediction, and pathway analysis. *Endocr Relat Cancer.* 2009;16:895–906.
- Zsippai A, Szabó DR, Tömböl Z, et al. Effects of mitotane on gene expression in the adrenocortical cell line NCI-H295R: a microarray study. *Pharmacogenomics.* 2012;13:1351–1361.

31. Caramuta S, Lee L, Ozata DM, et al. Clinical and functional impact of TARBP2 over-expression in adrenocortical carcinoma. *Endocr Relat Cancer*. 2013;20:551–564.
32. Chabre O, Libé R, Assié G, et al. Serum miR-483-5p and miR-195 are predictive of recurrence risk in adrenocortical cancer patients. *Endocr Relat Cancer*. 2013;20:579–594.
33. Fonseca AL, Kugelberg J, Starker LF, et al. Comprehensive DNA methylation analysis of benign and malignant adrenocortical tumors. *Genes Chromosomes Cancer*. 2012;51:949–960.
34. Barreau O, Assié G, Wilmot-Roussel H, et al. Identification of a CpG island methylator phenotype in adrenocortical carcinomas. *J Clin Endocrinol Metab*. 2013;98:E174–E184.
35. Young WF Jr. Clinical practice. The incidentally discovered adrenal mass. *N Engl J Med*. 2007;356:601–610.
36. Veytsman I, Nieman L, Fojo T. Management of endocrine manifestations and the use of mitotane as a chemotherapeutic agent for adrenocortical carcinoma. *J Clin Oncol*. 2009;27:4619–4629.
37. Nieman LK. Approach to the patient with an adrenal incidentaloma. *J Clin Endocrinol Metab*. 2010;95:4106–4113.
38. Zini L, Porpiglia F, Fassnacht M. Contemporary management of adrenocortical carcinoma. *Eur Urol*. 2011;60:1055–1065.
39. Berruti A, Baudin E, Gelderblom H, et al. Adrenal cancer: ESMO Clinical Practice Guidelines for diagnosis, treatment and follow-up. *Ann Oncol*. 2012;23(suppl 7):vii131–138.
40. Arlt W, Biehl M, Taylor AE, et al. Urine steroid metabolomics as a biomarker tool for detecting malignancy in adrenal tumors. *J Clin Endocrinol Metab*. 2011;96:3775–3784.
41. Blake MA, Cronin CG, Boland GW. Adrenal imaging. *AJR Am J Roentgenol*. 2010;194:1450–1460.
42. Young WF Jr. Conventional imaging in adrenocortical carcinoma: update and perspectives. *Horm Cancer*. 2011;2:341–347.
43. Petersenn S, Richter P, Broemel T, et al. CT criteria for adrenal cancer—analysis of the German ACC registry. *Exp Clin Endocrinol Diabetes*. 2013;121:OP8_48.
44. Szolar DH, Korobkin M, Reittner P, et al. Adrenocortical carcinomas and adrenal pheochromocytomas: mass and enhancement loss evaluation at delayed contrast-enhanced CT. *Radiology*. 2005;234:479–485.
45. Ilias J, Sahdev A, Reznick RH, Grossman AB, Pacak K. The optimal imaging of adrenal tumours: a comparison of different methods. *Endocr Relat Cancer*. 2007;14:587–599.
46. Park BK, Kim CK, Kim B, Lee JH. Comparison of delayed enhanced CT and chemical shift MR for evaluating hyperattenuating incidental adrenal masses. *Radiology*. 2007;243:760–765.
47. Zhang HM, Perrier ND, Grubbs EG, et al. CT features and quantification of the characteristics of adrenocortical carcinomas on unenhanced and contrast-enhanced studies. *Clin Radiol*. 2012;67:38–46.
48. Bauditz J, Quinkler M, Beyersdorff D, Wermke W. Improved detection of hepatic metastases of adrenocortical cancer by contrast-enhanced ultrasound. *Oncol Rep*. 2008;19:1135–1139.
49. Boland GW, Dwamena BA, Jagtiani Sangwaiya M, et al. Characterization of adrenal masses by using FDG PET: a systematic review and meta-analysis of diagnostic test performance. *Radiology*. 2011;259:117–126.
50. Deandreis D, Leboulloux S, Caramella C, Schlumberger M, Baudin E. FDG PET in the management of patients with adrenal masses and adrenocortical carcinoma. *Horm Cancer*. 2011;2:354–362.
51. Hahner S, Sundin A. Metomidate-based imaging of adrenal masses. *Horm Cancer*. 2011;2:348–353.
52. Kreissl MC, Schirbel A, Fassnacht M, et al. [123I]Iodometomidate imaging in adrenocortical carcinoma. *J Clin Endocrinol Metab*. 2013;98:2755–2764.
53. Mackie GC, Shulkin BL, Ribeiro RC, et al. Use of [18F]fluorodeoxyglucose positron emission tomography in evaluating locally recurrent and metastatic adrenocortical carcinoma. *J Clin Endocrinol Metab*. 2006;91:2665–2671.
54. Leboulloux S, Dromain C, Bonniaud G, et al. Diagnostic and prognostic value of 18-fluorodeoxyglucose positron emission tomography in adrenocortical carcinoma: a prospective comparison with computed tomography. *J Clin Endocrinol Metab*. 2006;91:920–925.
55. Williams A, Hammer GD, Else T. Transcutaneous biopsy of adrenocortical carcinoma is rarely helpful in diagnosis, potentially harmful, but does not affect patient outcome. *Endocr Rev*. 2013;34:MON-1.
56. Johanssen S, Hahner S, Saeger W, et al. Deficits in the management of patients with adrenocortical carcinoma in Germany. *Dtsch Arztebl Int*. 2010;107:885–891.
57. Sasano H, Suzuki T, Moriya T. Recent advances in histopathology and immunohistochemistry of adrenocortical carcinoma. *Endocr Pathol*. 2006;17:345–354.
58. Lau SK, Weiss LM. The Weiss system for evaluating adrenocortical neoplasms: 25 years later. *Hum Pathol*. 2009;40:757–768.
59. Volante M, Bollito E, Sperone P, et al. Clinicopathological study of a series of 92 adrenocortical carcinomas: from a proposal of simplified diagnostic algorithm to prognostic stratification. *Histopathology*. 2009;55:535–543.
60. Papotti M, Libé R, Duregon E, Volante M, Bertherat J, Tissier F. The Weiss score and beyond—histopathology for adrenocortical carcinoma. *Horm Cancer*. 2011;2:333–340.
61. Tissier F, Aubert S, Leteurte E, et al. Adrenocortical tumors: improving the practice of the Weiss system through virtual microscopy: a national program of the French Network INCa-COMETE. *Am J Surg Pathol*. 2012;36:1194–1201.
62. Duregon E, Fassina A, Volante M, et al. The reticulin algorithm for adrenocortical tumor diagnosis: a multicentric validation study on 245 unpublished cases. *Am J Surg Pathol*. 2013;37:1433–1440.
63. Beuschlein F, Obracay J, Saeger W, et al. Prognostic value of histological markers in localized adrenocortical carcinoma after complete resection. *Endocr Rev*. 2013;34:OR29–3.
64. Libé R, Borget I, Ronchi CL, et al. Prognostic factors of advanced unresectable by stage III and IV ENS@T adrenocortical carcinomas (ACC). *Endocr Abstr*. 2013;32:OC4.3.
65. Fassnacht M, Johanssen S, Quinkler M, et al. Limited prognostic value of the 2004 International Union Against Cancer staging classification for adrenocortical carcinoma: proposal for a revised TNM classification. *Cancer*. 2009;115:243–250.
66. Lughezzani G, Sun M, Perrotte P, et al. The European Network for the Study of Adrenal Tumors staging system is prognostically superior to the international union against cancer-staging system: a North American validation. *Eur J Cancer*. 2010;46:713–719.
67. Miller BS, Gauger PG, Hammer GD, Giordano TJ, Doherty GM. Proposal for modification of the ENSAT staging system for adrenocortical carcinoma using tumor grade. *Langenbecks Arch Surg*. 2010;395:955–961.
68. Volante M, Sperone P, Bollito E, et al. Matrix metalloproteinase type 2 expression in malignant adrenocortical tumors: diagnostic and prognostic significance in a series of 50 adrenocortical carcinomas. *Mod Pathol*. 2006;19:1563–1569.
69. Fenske W, Völker HU, Adam P, et al. Glucose transporter GLUT1 expression is an stage-independent predictor of clinical outcome in adrenocortical carcinoma. *Endocr Relat Cancer*. 2009;16:919–928.
70. Fassnacht M, Terzolo M, Allolio B, et al. Combination chemotherapy in advanced adrenocortical carcinoma. *N Engl J Med*. 2012;366:2189–2197.
71. Porpiglia F, Fiori C, Daffara F, et al. Retrospective evaluation of the outcome of open versus laparoscopic adrenalectomy for stage I and II adrenocortical cancer. *Eur Urol*. 2010;57:873–878.
72. Miller BS, Ammori JB, Gauger PG, Broome JT, Hammer GD, Doherty GM. Laparoscopic resection is inappropriate in patients with known or suspected adrenocortical carcinoma. *World J Surg*. 2010;34:1380–1385.
73. Brix D, Allolio B, Fenske W, et al. Laparoscopic versus open ad-

- renalectomy for adrenocortical carcinoma: surgical and oncologic outcome in 152 patients. *Eur Urol*. 2010;58:609–615.
74. Lombardi CP, Raffaelli M, De Crea C, et al. Open versus endoscopic adrenalectomy in the treatment of localized (stage I/II) adrenocortical carcinoma: results of a multiinstitutional Italian survey. *Surgery*. 2012;152:1158–1164.
 75. Mir MC, Klink JC, Guillotreau J, et al. Comparative outcomes of laparoscopic and open adrenalectomy for adrenocortical carcinoma: single, high-volume center experience. *Ann Surg Oncol*. 2013;20:1456–1461.
 76. Porpiglia F, Miller BS, Manfredi M, Fiori C, Doherty GM. A debate on laparoscopic versus open adrenalectomy for adrenocortical carcinoma. *Horm Cancer*. 2011;2:372–377.
 77. Jurowich C, Fassnacht M, Kroiss M, Deutschbein T, Germer CT, Reibetanz J. Is there a role for laparoscopic adrenalectomy in patients with suspected adrenocortical carcinoma? A critical appraisal of the literature. *Horm Metab Res*. 2013;45:130–136.
 78. Gaujoux S, Bertherat J, Dousset B, Groussin L. Laparoscopic adrenalectomy for adrenocortical carcinoma: a medico-surgical perspective. *Ann Endocrinol (Paris)*. 2012;73:441–447.
 79. Reibetanz J, Jurowich C, Erdogan I, et al. Impact of lymphadenectomy on the oncologic outcome of patients with adrenocortical carcinoma. *Ann Surg*. 2012;255:363–369.
 80. Gaujoux S, Al-Ahmadie H, Allen PJ, et al. Resection of adrenocortical carcinoma liver metastasis: is it justified? *Ann Surg Oncol*. 2012;19:2643–2651.
 81. Gaujoux S, Brennan MF. Recommendation for standardized surgical management of primary adrenocortical carcinoma. *Surgery*. 2012;152:123–132.
 82. Mihai R, Iacobone M, Makay O, et al. Outcome of operation in patients with adrenocortical cancer invading the inferior vena cava—a European Society of Endocrine Surgeons (ESES) survey. *Langenbecks Arch Surg*. 2012;397:225–231.
 83. Kerkhofs TM, Verhoeven RH, Bonjer HJ, et al. Surgery for adrenocortical carcinoma in The Netherlands: analysis of the national cancer registry data. *Eur J Endocrinol*. 2013;169:83–89.
 84. Lombardi CP, Raffaelli M, Boniardi M, et al. Adrenocortical carcinoma: effect of hospital volume on patient outcome. *Langenbecks Arch Surg*. 2012;397:201–207.
 85. Stojadinovic A, Ghossein RA, Hoos A, et al. Adrenocortical carcinoma: clinical, morphologic, and molecular characterization. *J Clin Oncol*. 2002;20:941–950.
 86. Fassnacht M, Johanssen S, Fenske W, et al. Improved survival in patients with stage II adrenocortical carcinoma followed up prospectively by specialized centers. *J Clin Endocrinol Metab*. 2010;95:4925–4932.
 87. Terzolo M, Angeli A, Fassnacht M, et al. Adjuvant mitotane treatment for adrenocortical carcinoma. *N Engl J Med*. 2007;356:2372–2380.
 88. Huang H, Fojo T. Adjuvant mitotane for adrenocortical cancer—a recurring controversy. *J Clin Endocrinol Metab*. 2008;93:3730–3732.
 89. Grubbs EG, Callender GG, Xing Y, et al. Recurrence of adrenal cortical carcinoma following resection: surgery alone can achieve results equal to surgery plus mitotane. *Ann Surg Oncol*. 2010;17:263–270.
 90. Berruti A, Fassnacht M, Baudin E, Hammer G, Haak H, Lebouleux S, Skogseid B, Allolio B, Terzolo M. Adjuvant therapy in patients with adrenocortical carcinoma: a position of an international panel. *J Clin Oncol*. 2010;28:e401–e402; author reply e403.
 91. Fassnacht M, Hahner S, Polat B, et al. Efficacy of adjuvant radiotherapy of the tumor bed on local recurrence of adrenocortical carcinoma. *J Clin Endocrinol Metab*. 2006;91:4501–4504.
 92. Sabolch A, Feng M, Griffith K, Hammer G, Doherty G, Ben-Josef E. Adjuvant and definitive radiotherapy for adrenocortical carcinoma. *Int J Radiat Oncol Biol Phys*. 2011;80:1477–1484.
 93. Habra MA, Ejaz S, Feng L, et al. A retrospective cohort analysis of the efficacy of adjuvant radiotherapy after primary surgical resection in patients with adrenocortical carcinoma. *J Clin Endocrinol Metab*. 2013;98:192–197.
 94. Khan TS, Imam H, Juhlin C, et al. Streptozocin and o,p'DDD in the treatment of adrenocortical cancer patients: long-term survival in its adjuvant use. *Ann Oncol*. 2000;11:1281–1287.
 95. Cazejust J, De Baère T, Aupeyin A, et al. Transcatheter arterial chemoembolization for liver metastases in patients with adrenocortical carcinoma. *J Vasc Interv Radiol*. 2010;21:1527–1532.
 96. Ripley RT, Kemp CD, Davis JL, et al. Liver resection and ablation for metastatic adrenocortical carcinoma. *Ann Surg Oncol*. 2011;18:1972–1979.
 97. op den Winkel J, Pfannschmidt J, Muley T, et al. Metastatic adrenocortical carcinoma: results of 56 pulmonary metastasectomies in 24 patients. *Ann Thorac Surg*. 2011;92:1965–1970.
 98. Kemp CD, Ripley RT, Mathur A, et al. Pulmonary resection for metastatic adrenocortical carcinoma: the National Cancer Institute experience. *Ann Thorac Surg*. 2011;92:1195–1200.
 99. Datrice NM, Langan RC, Ripley RT, et al. Operative management for recurrent and metastatic adrenocortical carcinoma. *J Surg Oncol*. 2012;105:709–713.
 100. Erdogan I, Deutschbein T, Jurowich C, et al. The role of surgery in the management of recurrent adrenocortical carcinoma. *J Clin Endocrinol Metab*. 2013;98:181–191.
 101. Assié G, Antoni G, Tissier F, et al. Prognostic parameters of metastatic adrenocortical carcinoma. *J Clin Endocrinol Metab*. 2007;92:148–154.
 102. Hermesen IG, Gelderblom H, Kievit J, Romijn JA, Haak HR. Extremely long survival in six patients despite recurrent and metastatic adrenal carcinoma. *Eur J Endocrinol*. 2008;158:911–919.
 103. De Francia S, Ardito A, Daffara F, et al. Mitotane treatment for adrenocortical carcinoma: an overview. *Minerva Endocrinol*. 2012;37:9–23.
 104. Haak HR, Hermans J, van de Velde CJ, et al. Optimal treatment of adrenocortical carcinoma with mitotane: results in a consecutive series of 96 patients. *Brit J Cancer*. 1994;69:947–951.
 105. Baudin E, Pellegriti G, Bonnay M, et al. Impact of monitoring plasma 1,1-dichlorodiphenildichloroethane (o,p'DDD) levels on the treatment of patients with adrenocortical carcinoma. *Cancer*. 2001;92:1385–1392.
 106. Hermesen IG, Fassnacht M, Terzolo M, et al. Plasma concentrations of o,p'DDD, o,p'DDA, and o,p'DDE as predictors of tumor response to mitotane in adrenocortical carcinoma: results of a retrospective ENS@T multicenter study. *J Clin Endocrinol Metab*. 2011;96:1844–1851.
 107. Bourdeau I, MacKenzie-Feder J, Lacroix A. Recent advances in adrenocortical carcinoma in adults. *Curr Opin Endocrinol Diabetes Obes*. 2013;20:192–197.
 108. Glover AR, Ip JC, Zhao JT, Soon PS, Robinson BG, Sidhu SB. Current management options for recurrent adrenocortical carcinoma. *Onco Targets Ther*. 2013;6:635–643.
 109. Mauclère-Denost S, Lebouleux S, Borget I, et al. High-dose mitotane strategy in adrenocortical carcinoma: prospective analysis of plasma mitotane measurement during the first 3 months of follow-up. *Eur J Endocrinol*. 2012;166:261–268.
 110. Kerkhofs T, Baudin E, Terzolo M, et al. Comparison of two mitotane starting dose regimens in patients with advanced adrenocortical carcinoma. *J Clin Endocrinol Metab*. 2013;98:4759–4767.
 111. Kroiss M, Quinkler M, Johanssen S, et al. Sunitinib in refractory adrenocortical carcinoma: a phase II, single-arm, open-label trial. *J Clin Endocrinol Metab*. 2012;97:3495–3503.
 112. Sperone P, Ferrero A, Daffara F, et al. Gemcitabine plus metronomic 5-fluorouracil or capecitabine as a second-/third-line chemotherapy in advanced adrenocortical carcinoma: a multicenter phase II study. *Endocr Relat Cancer*. 2010;17:445–453.
 113. Polat B, Fassnacht M, Pfreundner L, et al. Radiotherapy in adrenocortical carcinoma. *Cancer*. 2009;115:2816–2823.
 114. Samnotra V, Vassilopoulou-Sellin R, Fojo AT, et al. A phase II trial

- of gefitinib monotherapy in patients with unresectable adrenocortical carcinoma (ACC). In: Proceedings from the American Society of Clinical Oncology; June 1–5, 2007; Chicago, IL. Abstract 15527.
115. Quinkler M, Hahner S, Wortmann S, et al. Treatment of advanced adrenocortical carcinoma with erlotinib plus gemcitabine. *J Clin Endocrinol Metab.* 2008;93:2057–2062.
 116. Kroiss M, Reuss M, Kuhner D, et al. Sunitinib inhibits cell proliferation and alters steroidogenesis by down-regulation of HSD3B2 in adrenocortical carcinoma cells. *Front Endocrinol (Lausanne).* 2011;2:27.
 117. Mariniello B, Rosato A, Zuccolotto G, et al. Combination of sorafenib and everolimus impacts therapeutically on adrenocortical tumor models. *Endocr Relat Cancer.* 2012;19:527–539.
 118. Xu YZ, Zhu Y, Shen ZJ, et al. Significance of heparanase-1 and vascular endothelial growth factor in adrenocortical carcinoma angiogenesis: potential for therapy. *Endocrine.* 2011;40:445–451.
 119. Wortmann S, Quinkler M, Ritter C, et al. Bevacizumab plus capecitabine as a salvage therapy in advanced adrenocortical carcinoma. *Eur J Endocrinol.* 2010;162:349–356.
 120. Berruti A, Sperone P, Ferrero A, et al. Phase II study of weekly paclitaxel and sorafenib as second/third-line therapy in patients with adrenocortical carcinoma. *Eur J Endocrinol.* 2012;166:451–458.
 121. García-Donas J, Polo SH, Guix M, et al. Phase II study of dovitinib in first line metastatic or (nonresectable primary) adrenocortical carcinoma (ACC): SOGUG study 2011-03. In: Proceedings from the American Society of Clinical Oncology; May 31-June 4, 2013; Chicago, IL. Abstract 4587.
 122. Naing A, Lorusso P, Fu S, et al. Insulin growth factor receptor (IGF-1R) antibody cixutumumab combined with the mTOR inhibitor temsirolimus in patients with metastatic adrenocortical carcinoma. *Br J Cancer.* 2013;108:826–830.
 123. Fraenkel M, Gueorguiev M, Barak D, Salmon A, Grossman AB, Gross DJ. Everolimus therapy for progressive adrenocortical cancer. *Endocrine.* 2013;44:187–192.
 124. Hahner S, Kreissl MC, Fassnacht M, et al. [131I]iodometomidate for targeted radionuclide therapy of advanced adrenocortical carcinoma. *J Clin Endocrinol Metab.* 2012;97:914–922.
 125. Zhang H, Neely L, Lundgren K, et al. BIIB021, a synthetic Hsp90 inhibitor, has broad application against tumors with acquired multidrug resistance. *Int J Cancer.* 2010;126:1226–1234.
 126. Nilubol N, Zhang L, Shen M, et al. Four clinically utilized drugs were identified and validated for treatment of adrenocortical cancer using quantitative high-throughput screening. *J Transl Med.* 2012;10:198.
 127. Ferrero A, Sperone P, Ardito A, et al. Metronomic chemotherapy may be active in heavily pre-treated patients with metastatic adrenocortical carcinoma. *J Endocrinol Invest.* 2013;36:148–152.
 128. Chacón R, Tossen G, Loria FS, Chacón M. Case 2. Response in a patient with metastatic adrenal cortical carcinoma with thalidomide. *J Clin Oncol.* 2005;23:1579–1580.
 129. Dobrosotskaya IY, Hammer GD, Schteingart DE, Maturen KE, Worden FP. Mebendazole monotherapy and long-term disease control in metastatic adrenocortical carcinoma. *Endocr Pract.* 2011;17:e59–e62.
 130. Poli G, Guasti D, Rapizzi E, et al. Morphofunctional effects of mitotane on mitochondria in human adrenocortical cancer cells. *Endocr Relat Cancer.* 2013;20:537–550.
 131. Hescot S, Slama A, Lombès A, et al. Mitotane alters mitochondrial respiratory chain activity by inducing cytochrome c oxidase defect in human adrenocortical cells. *Endocr Relat Cancer.* 2013;20:371–381.
 132. Stigliano A, Cerquetti L, Borro M, et al. Modulation of proteomic profile in H295R adrenocortical cell line induced by mitotane. *Endocr Relat Cancer.* 2008;15:1–10.
 133. Lehmann TP, Wrzesiski T, Jagodzinski PP. The effect of mitotane on viability, steroidogenesis and gene expression in NCI-H295R adrenocortical cells. *Mol Med Rep.* 2013;7:893–900.
 134. D'Avolio A, De Francia S, Basile V, et al. Influence of the CYP2B6 polymorphism on the pharmacokinetics of mitotane. *Pharmacogenet Genomics.* 2013;23:293–300.
 135. Terzolo M, Baudin AE, Ardito A, et al. Mitotane levels predict the outcome of patients with adrenocortical carcinoma treated adjuvantly following radical resection. *Eur J Endocrinol.* 2013;169:263–270.
 136. van Erp NP, Guchelaar HJ, Ploeger BA, Romijn JA, Hartigh Jd, Gelderblom H. Mitotane has a strong and a durable inducing effect on CYP3A4 activity. *Eur J Endocrinol.* 2011;164:621–626.
 137. Chortis V, Taylor AE, Schneider P, et al. Mitotane therapy in adrenocortical cancer induces CYP3A4 and inhibits 5 α -reductase, explaining the need for personalized glucocorticoid and androgen replacement. *J Clin Endocrinol Metab.* 2013;98:161–171.
 138. Kroiss M, Quinkler M, Lutz WK, Allolio B, Fassnacht M. Drug interactions with mitotane by induction of CYP3A4 metabolism in the clinical management of adrenocortical carcinoma. *Clin Endocrinol (Oxf).* 2011;75:585–591.
 139. Daffara F, De Francia S, Reimondo G, et al. Prospective evaluation of mitotane toxicity in adrenocortical cancer patients treated adjuvantly. *Endocr Relat Cancer.* 2008;15:1043–1053.
 140. Gross DJ, Munter G, Bitan M, et al. The role of imatinib mesylate (Glivec) for treatment of patients with malignant endocrine tumors positive for c-kit or PDGF-R. *Endocr Relat Cancer.* 2006;13:535–540.